

HOPE!



The Newsletter of Operation Restore Hope Australia
website: <http://www.operationrestorehope.org>

Volume 3 Number 4

May 2013

Now in our 20th Year! over 20 years of service in the Philippines



Three babies ready for surgery and a second chance in the morning line-up.

Operation Restore Hope (ORH) is in its 20th year of operating having commenced in 1994 in Cebu, in the Visayas region of the Philippines. Having now completed more than 2,300 operations and provided countless other medical services, especially dental, we continue to field three surgical missions per year to the Philippines: 2 to Cebu and 1 to Luzon.

Largest Mission Ever

This year, we were invited for the first time to operate at the H W Miller Memorial Hospital. With their facilities we were able to have our most successful mission ever in

terms of throughput, operating on 86 patients in one week. We are encouraged by this new relationship and due to its success, plans are already underway to return for a mission next year.

Staying in Cebu.

The other Cebu mission will remain at our home base since our inception, Lapu Lapu District Hospital; a facility and community we have been committed to for 20 years. Celebrations are currently being planned to mark this momentous milestone in 2014.

This year the Luzon mission coordinated by Operation Restore Hope New Zealand moved from the north of Metro Manila to the

(continued on page 2 column 1)

A Letter from Dr Hodgkinson



Operation Restore Hope's long but valuable road

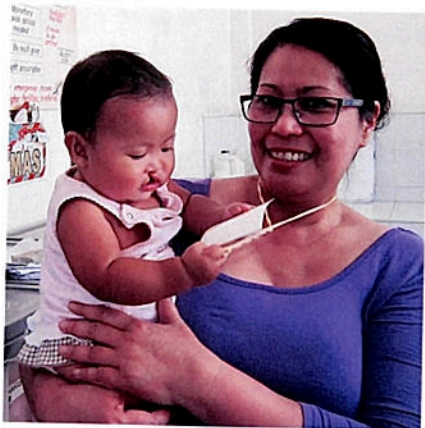I recently attended a meeting of international plastic surgeons in Singapore. We all attend these meetings to share vital long term experiences in all areas of plastic surgery, which includes charity surgery. One of my Italian colleagues travelled recently to Gabon in Western Africa where he is setting up a charity, and described in graphic details his problems.

I reflected with him on the long road he would travel, trying to give him short cuts and tips to achieve good surgical results for the unfortunate children he encountered with cleft lip and palate, burns and tumours who are suffering by not having plastic surgery available in a decent hospital. These poor young patients afflicted by a surgically correctable disease are in a tragic situation that can unfortunately at this stage only be corrected by charity surgery.

(continued on page 4 column 1)

My first ORH

Dr Chi Duong tells the story of his first mission to Cebu



We landed to tropical rain downpouring on Friday 19th October, 2012 at Cebu. I had mixed emotions as we travelled back to our luxury hotel. I was filled with sorrow at the destitution of so many young children but anxious to contribute in some small way.

In some respects, coming to the Philippines reminded me of my visits to Vietnam. I could see that there was an obvious need for assistance to the poor.

Disparity of wealth

The disparity of wealth was evident in Cebu. All around me were families who lived on the edge of poverty. Street children boldly played music with improvised instruments and danced at busy traffic intersections. Beggars who were disheveled and unkempt sitting by the side of the road.

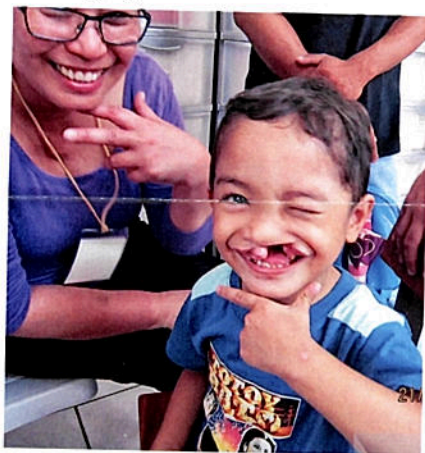But, added to this undertone were young adults travelling by scooters and bicycles to university and several luxury cars busily scooting around the city.

Few worldly possessions

The families that accompanied each cleft lip and palate patient were of lower socio-economic background. Their worldly possessions comprised of a total of 3-4 full plastic bags.

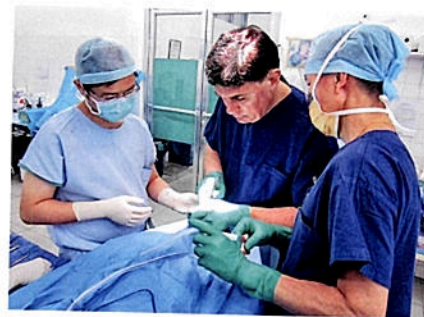

On the screening day there were close to 100 children who arrived expecting that their turn had come to have life-changing surgery. The palpable disappointment and looks of anguish of almost half those families after being declined was heart wrenching. It isn't fair. In first world countries no children with this type of anomaly would normally be told to wait indefinitely for surgery.



Some were lucky

The fortunate children and their families were provided with accommodation by the Rotary team until they had their operations. The majority of the operations were to repair cleft lips (unilateral or bilateral) but we also repaired cleft palates and extracted some decayed teeth.



In the morning, before the next day's operating started we would review the patients from the previous day. The beautiful smiles of the children were a constant and enduring reminder of why we toiled each day. The complete trust of the parents in the surgeon's skills was obvious and in stark contrast to the questioning and doubt in western patient's families.

The value of improvisation

The limitation of modern equipment taught me the value of improvisation and team work to provide best quality care in a third world setting. It is costly to provide this type of service, even without the inclusion of the surgeon's fees. The disposable materials (anesthetic gases, drugs, medications, gloves, masks, sutures) all add up and without the kind donations of various organizations and hospitals this would not have been possible for the past 20 years.

Short but intense experience

As I boarded the plane back from Cebu I dwelled upon the short but intense experience I had been part of for the last week. I hope that this yearly medical mission can continue indefinitely but am realistic that this requires both funding as well as the goodwill and experience of skilled surgeons.

Unreservedly I am richer because of the opportunity I was given to work alongside a warm and friendly team whose sole purpose was to bring back the smiles of so many young children.

As I begin the next stage of my training for a medical degree, I sincerely hope that one day I will myself be able to contribute regularly to this charitable service.

Now in our 20th Year!

(continued from P.1)

southern province of Batangas just a few hours south of Manila. This is a high area of need that is not being serviced by other missions. The team had a very successful mission especially considering all the logistics of operating in a new location.

Congratulations to all of our volunteers!

Vale

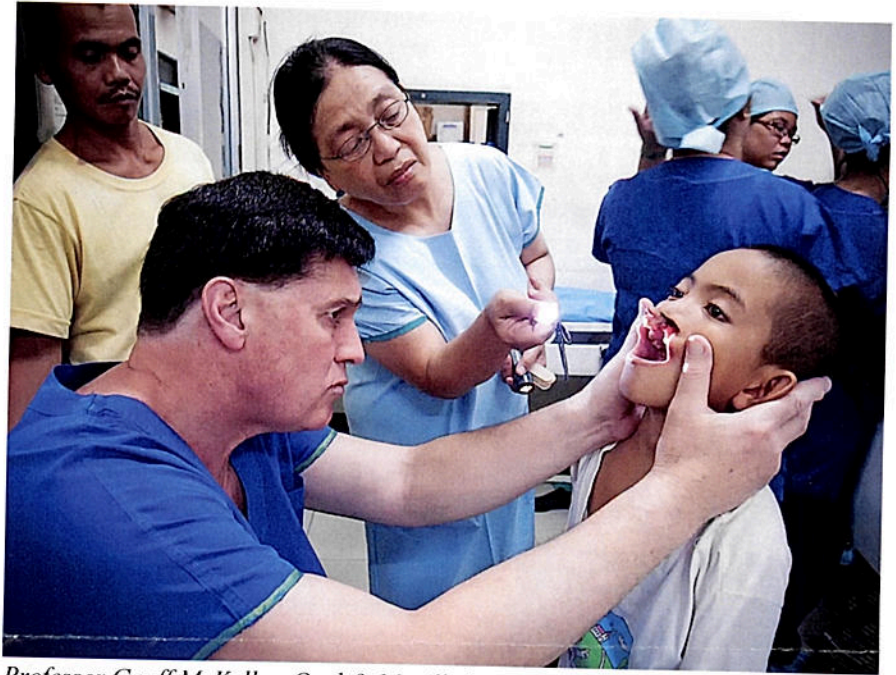Professor Geoff McKellar, Oral & Maxillofacial Surgeon

Professor Geoff McKellar shared his time, expertise and heartfelt commitment since he joined his first mission to Lapu Lapu District Hospital in Cebu in 1997. Since then, he returned every year to participate in surgical missions and was thereby instrumental in changing the lives of countless children who without charitable assistance would have gone unaided.

All who came to know him through working with him hand in hand both in Australia and the Philippines hold dear the memory of our colleague and give thanks for his immeasurable contribution. While his spirit has left us early our memory of all his good works will remain and encourage us to ensure that these missions carry on.


Mr Charles John Grace, Chartered Accountant

Charles John Grace gave his services generously, thoughtfully and enthusiastically. He provided the charity with pro bono accounting, auditing and financial services from its early days in the 1990s when it struggled to make ends meet (before it gained DGR – deductible gift recipient status) right up until he lost his bravely fought battle with cancer earlier this year.



Professor Geoff McKellar, Oral & Maxillofacial Surgeon examines a patient in the Philippines before surgery.

Charles John (or CJG as he was lovingly known) was always one of the quiet achievers in the background of the charity, working tirelessly behind the scenes without recognition doing tasks that were critical to the charity's survival and development. His smile was also ever present at our many fundraisers and functions. We will hold dear and foster his example of generosity, loyalty and service to others.



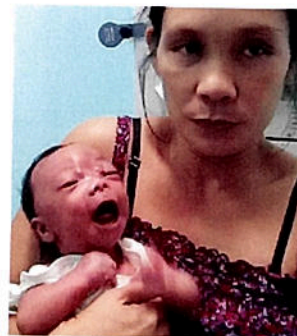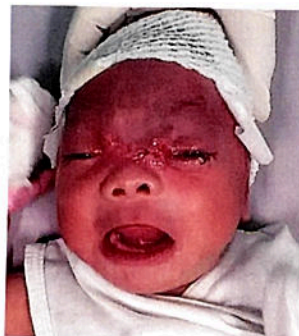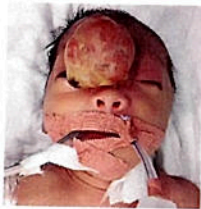Mr Charles John Grace, Chartered Accountant

Operation Restore Hope conveys our condolences to the families and friends of our lost colleagues as we give thanks for the gifts that they shared with us.

Vale, Geoff & CJG.

Youngest Patient Ever (only 11 days old!)

A great achievement has been the ability to care for younger babies than ever before! Through our collaboration with local plastic



Our 11 days old patient: pre-operation, post-operation, and with his mother.

surgeon, Dr Taps Gurango and the Gurango Mijares Craniofacial Foundation our patients have access to the well equipped neonatal intensive care unit at PCMC

(Philippine Children's Medical Center). This unit has allowed us to treat newborns.

Early treatment not only reduces the mortality rate for some of these

children but also provides them with a better chance to thrive in their early development.

Here is a recent case of a baby who was brought to us at birth with a meningocele (a hernial protrusion

of the meninges or covering of the brain through a defect in the skull). With quick action, he had his initial surgery 11 days later, and a successful outcome.

Letter from Dr Hodgkinson

(continued from front page)

Children lying on cardboard destitute or more than one on a rustic bed was a circumstance we first encountered in our small hospital in Lapu-Lapu 20 years ago. There was virtually no equipment or medications in the hospital, primitive lights for the operating room,



**Check us out
on Facebook!**

Visit us on FB:

<http://www.facebook.com/pages/Operation-Restore-Hope/127851487242137>

Just a Reminder...

Operation Restore Hope membership renewals are now due!

Please use the form below to renew and help us continue our work - many thanks.

Not a member? Why not join!

Membership is only \$20 per year and Life Membership \$100.

non-functional safety equipment. We had to provide almost everything.

We began by a change in the whole infrastructure of the hospital providing a truckload of beds, operating tables, anaesthetic monitors and safety equipment and the training of nursing staff, converting the little hospital into a hospital that now stands as a flagship for other sites in the Philippines and welcomes other charity groups into the hospital to perform surgery.


In Manila we have achieved wonders by supporting our local plastic surgeon who corrects patients with difficult and staged craniofacial problems at the PCMC.

Our NAM program is unique amongst surgical charities internationally by being set up to help reduce the severity of the cleft lip and palate before the surgeon performs the procedure, thus resulting in a better primary repair result. This was the envy of a senior plastic surgeon that I met in Chile at an international meeting who said they did not even have that service at his large public hospital in Dublin.

The amazing progress made by our charity in 20 years has only taken place with the commitment of time, money and medical personnel, and I encouraged my colleague from Italy that getting on this long journey would, I hope, in

20 years allow him to reflect back on great achievement.

After two decades, Operation Restore Hope has changed the lives of thousands of children in the Philippines. Our personnel maintain the highest standards of paediatric plastic surgery and comply with the World Health Organisation guidelines for safe surgery. Thanks to our volunteers and financial supporters you can be proud of your association with Operation Restore Hope.



Special thanks to Ulco for customising 3 anaesthetic machines for us in the Philippines at no cost!

Our Sponsors:



HOPE! printed by

DA PRINTING & PUBLISHING SERVICES P/L

OPERATION RESTORE HOPE Australia to repair a facial cleft is approximately \$500 AUD per operation. The more donations we receive, the more children we can help.

No funds received are spent on administrative, accounting, advertising or infrastructure costs. All membership fees and donations are spent directly on surgeries performed.

You can also become a Life Member of Operation Restore Hope Australia or just join for a year. Your fee or donation will help fund the cost of a child's surgery.

Name _____

Address _____

Email _____

Phone _____

Donations over \$2.00 are fully tax deductible and are payable to "Operation Restore Hope Philippines Relief Fund"

I wish to make a donation of \$ _____

Memberships are not tax deductible and are payable to 'Operation Restore Hope Australia'

Enclosed is my \$100 Lifetime Membership fee

Enclosed is my \$20 Annual Membership fee

TOTAL PAYMENT: \$ _____

Method of Payment:

Cheque enclosed MasterCard Visa

Credit Card No. _____

Signature _____

Expiry Date _____